

Review article



THE ROLE OF MOUTH BREATHING ON DENTITION DEVELOPMENT AND FORMATION

Zornitsa Valcheva¹, Hristina Arnautska¹, Mariana Dimova², Gergana Ivanova¹, Iliyana Atanasova¹

1) Department of Orthodontics, Faculty of Dental Medicine, Medical University - Varna, Bulgaria

2) Department of Prosthetic Dentistry, Faculty of Dental Medicine, Medical University - Sofia, Bulgaria

ABSTRACT

Introduction: The influence of mouth breathing on the development of the dentition and dento-facial deformities is a problem causes concerns among the medical specialists. Mouth breathing has a major impact on the development of the maxillo-facial region, occlusion and muscle tonus.

Aim: The aim of this study is to assess the relationship between etiological factors, pathogenesis and disturbances in mastication in mouth breathing patients.

Material and methods: For this article, data is obtained from 43 medical, literary sources.

Results: Literature review demonstrated that mouth breathing habit affects mostly children aged 7 - 12 years. In the vast majority of studies, the authors established a relation between mouth breathing and the development of maxillo-facial region and occlusion. The malocclusions described include a distal occlusion, anterior open bite, increase overjet, posterior crossbite, crowding and average incisors inclination disturbances. These clinical conditions become more complicated in the late-mixed and permanent dentition if mouth breathing continues to persist.

Conclusion: The habitual mouth breathing is a great medical problem nowadays. An increasing numbers of patients with this condition although the development of technology for early diagnostic is embarrassing. This condition is strongly related with different malocclusions such as anterior open bite, overjet, distal occlusion, underdeveloped and narrow upper jaw, increased anterior facial height.

Keywords: mouth breathing, dentition development, dentition formation,

Both - nose and mouth breathing provide lungs with oxygen but with extremely disparate effects on the body and different levels of oxygen supply. Human beings are designed to be nose breathers but various reasons can force them to adapt by breathing through their mouth, and this can have wide-ranging consequences. No creature except human sleeps with open mouth and breathes through the mouth and, in fact, it is deemed that only civilized human beings change natural functions in such a manner compared

with primitive people and native tribes who have normal breathing without exception [1]. Probably this unnatural breath pattern of civilized people has been acquired because of improved wellbeing and life style changes such as limiting environmental influence and goods oversupply.

The purpose of breathing is to oxygenate the body and to remove the waste carbon dioxide. The body requires approximately 2 - 3 % of oxygen concentration in inhaled air, while its atmospheric level is 21 %, so there is no need for oxygen to be stored. Body can tolerate carbon dioxide concentration about 6.5 %, but atmosphere level is 0.03 % [2, 3, 4, 5]. So body should accumulate produced carbon dioxide in lungs and blood. Carbon dioxide expresses several functions in the body: to facilitate the release of oxygen from haemoglobin, to trigger the inhalation, to regulate pH through buffering with bicarbonates or carbonic acid. All these functions are limited or disturbed in mouth breathers. Respiration is a natural, spontaneous process which is not oxygen dependent but the subject of carbon dioxide concentration in the pulmonary alveoli and blood.

Nose breathing controls the volume of inhaled and, more important, the volume of exhaled air. Body oxygenation occurs during exhalation not during inhalation. The negative pressure created in lungs upon exhalation in nose breathing pattern versus mouth breathing provides more time for binding of oxygen to haemoglobin in the blood. This process requires appropriate concentration of carbon dioxide in the blood. For oxygenation of brain and muscle cells, the level of carbon dioxide has to be 5 % in alveoli and arterial blood [2 - 9].

Nitric oxide has a role in the process of oxygenation and oxygen binding efficiency as well. The oxygen concentration in blood increases up to 18% [7, 10 - 12]. In fact, in mouth breathers, the carbon dioxide levels decrease in lungs and blood fall, and this leads to lower oxygen supply of the body cells.

The problem with mouth breathing begins with a change in tongue position which is meant to naturally rest on the roof of the mouth, but it drops down to the floor of the mouth and consequently inadequate skeletal growth results in the development of so called long face syndrome.

EXPOSITION

I. DEFINITION:

Mouth breathing is clinically observed in patients with some nasal obstruction as well as in those who have a habit to stay and sleep with open mouth. We define a difficult nasal breathing when there is a partial or full, temporary or permanent obstruction of the upper airways, and the processes of breathing in and out are performed through the mouth. Mouth breathing is a deleterious habit. It may be determined as an oral habit in the cases when there is no anatomical factors and obstacle for nose breathing [13].

C. V. Tomes introduced in 1872 the term „adenoid facies“ and determined typical dentofacial appearance in patients with nasal breathing difficulties. The face becomes long and narrow.

Open bite, *hyperdivergent growth pattern, proclined upper incisors*, increased lower facial height, steeper mandibular plane angle, lowering of the chin and increase in the gonial angle are among these features. A little later, in 1889, Kingsley undertook another study, according to which we have a normal skeletal formation and development in children with severe nose breathing difficulties [14]. Similar researches are aiming to compare the dentofacial development of mouth breathers towards nose-breathing patients and have been carried out by other scientists too [15 – 18].

In Chacker's opinion, nasal breathing difficulties are defined as a long or prolonged exposition of the frontal facial tissues to the drying up effect of the inhaled air [16, 17].

Sassouni determined mouth breathing as a habitual respiration through the mouth instead of the nose [16 – 18]. A little later, Merle offered the term oronasal breathing instead of oral or mouth breathing as he considers this term is more correct and exact [16, 17].

Nowadays the viewpoint is adopted that mouth breathers are those people who breathe through the mouth even when at rest [19]. They should be distinguished from nasal breathers who breathe through the mouth only upon intensive physical loads but through the nose at rest [19].

II. ETIOLOGY OF MOUTH BREATHING:

Slim and Finn [16, 17] classified mouth breathing in 1987 as:

- obstructive;
- anatomical;
- habitual.

The etiological factors can be:

1. Nasal obstruction due to:

- pharyngeal lymphoid tissue hypertrophy;
- intranasal deformities – nasal septum deviation, polypus, tumour, postoperative cicatrix;
- allergic rhinitis;
- enlarged conchae – due to allergies, chronic infections of the mucous membrane.

2. Bad habit to staying and sleeping with mouth open not related to medical conditions.

III. PATHOGENESIS OF MOUTH BREATHING

The change in the way of breathing leads to a change in the jaw, tongue and head position. The balance between the tongue action, on the one hand, and the mimic and masticatory muscles, on the other hand, is disturbed. The “forming” action to the mid-face of the air passing through nasal cavity is disturbed too, and it influences normal palatal development. In mouth breathing pattern the tongue is usually shifted back and *downwards* and doesn't participate in the development of the hard palate, which results in the formation of a deep gothic palate. A forward head posture is developed in order to make easier inhalation through mouth, the lower jaw is underdeveloped and placed downward and backwards, and this leads to its distal position and overjet formation. Taut cheek muscles apply an increased external force to the upper jaw which causes V-shaped form.

Pathogenesis of mouth breathing

↓

*Changed position of tongue, jaws and head
Tongue occupying a back and lower position*

↓

Mandible dropped down,

↓

Disproportion between jaws and teeth

↓

Imbalance between masticatory, mimic and tongue muscles

↓

Adenoid facies or long face syndrome

IV. CLINICAL PATTERN OF MOUTH BREATHING PATIENTS

Mouth breathing patients have characteristic intraoral and extraoral symptoms. In the period between 1970 and 1980, Linder-Aronson [21, 22] reported the connection between mouth breathing and craniofacial appearance including long face, anterior open bite, overjet, posterior crossbite [23,24, 25, 26]. Following extraoral signs are apparent:

- lip incompetence;
- a short upper lip;
- dry and cracked lips;
- an increased lower facial third;
- an increased mandibular angle;
- dark circles under the eyes;
- narrow nostrils;
- a small and tip-tilted nose;
- smoothed nasolabial folds;
- a typical head position – in extension.

The most common and characteristic intraoral signs include [19 – 22, 23,27-30]:

- a deep or gothic palate;
- a V-shaped upper dental arch;
- posterior crossbite;
- anterior open bite;
- an overjet;
- class II malocclusion;

- gingivitis in frontal teeth.

According to Subtelny [31], the deep palate in mouth breathers is an illusion due to the upper jaw compression. Brodie thinks that jaw compression is due to an imbalance between cheek muscles and tongue muscles [32 – 34]. As the pressure in the area of premolars and molars is bigger than this in the area of canines, the changes in the posterior region are greater. Angle, Brodie, Hawking and Moyers accept the role of muscles in upper jaw formation, while other authors like Brash, Linder-Aronson and Backstrom disclaim this theory.

Angle and Hawking do not find a deviation in the dental arch form in mouth breathing children versus such breathing through the nose. As opposed to this, many authors find crooked frontal teeth more often in upper jaw [35-37].

The Joshi's studies confirm that class II malocclusion is more often and related with mouth breathing patients [38, 39]. Angle, Huber and Reynolds [40] and Moyers report that mouth breathing has an impact on the development of all classes of malocclusions. In contrast to the above indicated, Howard examines a lot of mouths breathing children who are with class I molar relationship. According to Rakosi and Schilli mouth breathing plays a role in aetiology and pathogenesis of class III malocclusion [41].

A not-insubstantial percentage of mouth breathing children have a deep bite. It is most often due to the distal position of the lower jaw and lack of incisor contact. Hawkins and Rachel found that deep bite is due to under-

development of premolars and molars segments.

V. METHODS OF RESEARCH AND DIAGNOSTICS OF MOUTH BREATHING.

Clinical and functional tests are made to diagnose the breathing pattern and to differentiate nasal breathing difficulties from the bad habit to stay and sleep with mouth open[42]. Following tests belong to the clinical methods:

- Dental mirror is placed at rest in front of the patient's nostrils, the one nostril is closed, and the patient is asked to make several respiratory movements. If the mirror becomes blurred and foggy, this would mean that the patient is able to breathe through this nostril. The same procedure is repeated for the other nostril too (Mirror test, Fog test);

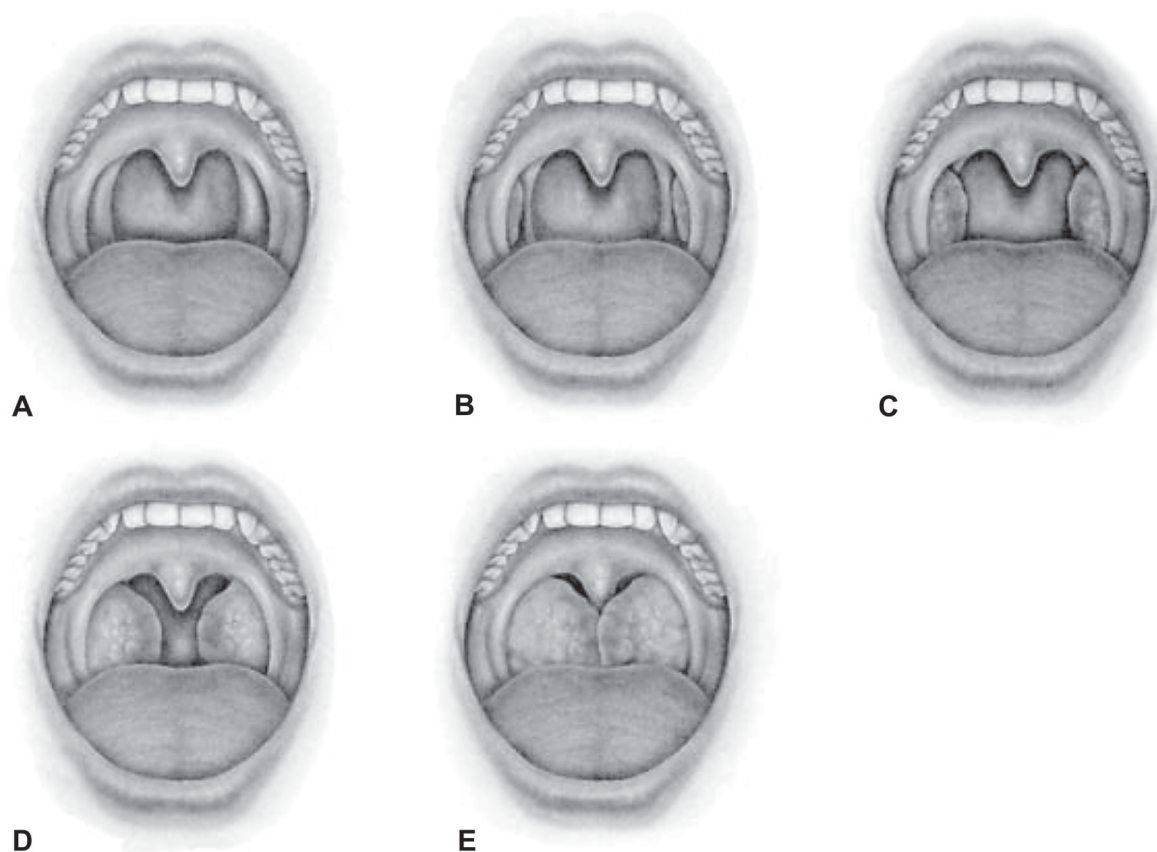
- A tiny piece of paper or cotton pellet is placed at rest underneath the nostrils. If they flutter upon several breathing in and out through the nose, then the child is able to breathe through the nose;

- If sip of water is kept in mouth up to 1 minute without swallowing or spilling it out, then the child can breathe through the nose (Massler's butterfly test);

- If the child doesn't open its mouth upon complete contact of lips and several consecutive squats are done, then it can breathe through the nose.

There are objective anatomical characteristics which show the presence of a difficult nasal breathing. The size of tonsils (fig. 1) is also determined during the clinical intraoral examination [43]:

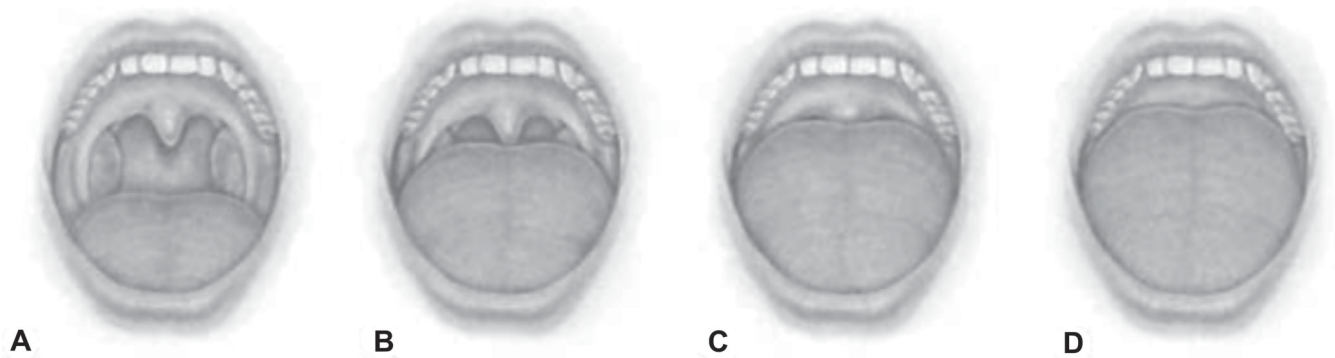Fig. 1. Illustration of tonsil grades [43]



A. TS 0 – status post tonsillectomy; B. TS 1 – tonsils are behind the anterior palatal arches, the posterior and lateral walls of mesopharynx are accessible for examination; C. TS 2 – tonsils placed medially out of the arches but do not cover the lateral columns; D. TS 3 – tonsils cover the lateral columns but do not reach the midline; E. TS 4 – tonsils touch each other in the midline, the so called “kissing tonsils”

The widely adopted at a global scale Friedman score is used for assessment of the obstruction stage on level mesopharynx on the part of the tongue. It is a modification of the Mallampati classification upon which the tongue is in the oral cavity during the examination [43].

Fig. 2. Graphic representation of (A) Mallampati score classes



A. Class I – When tongue is in the oral cavity, tonsils, lateral columns and the whole uvula are easy to examine; B. Class II – The whole soft palate and the uvula are visible, excluding palatal tonsils; C. Class III – A part of the soft palate is visible but not the whole uvula; D. Class IV – The soft palate is visible only.

CONCLUSION

The habit to breathe through the mouth instead of the nose is an exclusively topical problem nowadays. Despite the development of medicine and contemporary early diagnostic tools, the percentage of mouth breathing children grows. The clinical symptoms are diverse in respect of severity depending on mouth breathing duration. If not

treated developmental deficiencies progress and thereby the severity of structural changes in the body rises. Mouth breathing impacts everything - facial development, alignment, functioning and growth of the body. We often diagnose such patients with anterior open bite, an overjet, a distal position of the lower jaw, a narrowing of the upper jaw and an increase in the height of the lower facial third.

REFERENCES:

1. Wagner C. Habitual mouth-breathing: its causes, effects, and treatment. New York: G.P. Putnam's Sons. 1881. p. 10-11.
2. West JB. Respiratory Physiology: The essentials. Philadelphia: Lippincott Williams & Wilkins. 2008. p. 12-24, 36-55.
3. West JB. Pulmonary Pathophysiology: The essentials. Philadelphia: Lippincott Williams & Wilkins. 2011. p. 3-34.
4. Tortora GJ, Grabowski SR. Principles of Anatomy and Physiology. 10th ed. New York: Harper Collins College Publishers. 2003. p. 252, 744, 745.
5. Barrow A, Jaideep JJ, Pandit, Lung ventilation and the physiology of breathing. *Surgery*. 2017 May; 35(5): 227-233. [CrossRef]
6. Seeley RR, Stephens TD, Tate P. Anatomy & Physiology. International edition. McGraw-Hill Education. 2016. p. 663.
7. Berne RM, Levy MN. Principles of Physiology. 3 edition. Mosby. 2000. p. 680.
8. Rhoades RA. Part V: Respiratory Physiology. In: Medical Physiology: Principles for Clinical Medicine. Editors Rhoades RA, Bell DR. Third edition. Wolters Kluwer/LWW; February 8, 2008. Chapter 18, 19, 20, 21; pp.319-390. [Internet]
9. Van de Graaff KM, Fox SR. Human Anatomy and Physiology. 6th edition. McGraw Hill Higher Education. 2001. p. 607, 609, 614, 615.
10. Schedin U, Norman M, Gustafsson LE, Herin P, Frostell D. Endogenous nitric oxide in the upper airways of health newborn infants. *Pediatr Res*. 1996 Jul;40(1):148-51. [PubMed]
11. Page DC. Your Jaws - Your Life: Alternative Medicine. 2nd edition. Smilepage Pub. Jan. 2003. p.35.
12. Lundberg JO, Farkas-Szallasi T, Weitzberg E, Rinder J, Lidholm J, Anggaard A, et al. High nitric oxide production in human paranasal sinuses. *Nat Med*. 1995 Apr;1(4):370-3. [PubMed]
13. Arathi Rao, Principle and Practice of Pedodontics. 3rd edition. New Delhi. 2012, p.169, 170.
14. De Menezes VA, Leal RB, Pessoa RS, Pontes RM. [Prevalence and factors related to mouth breathing in school children at the Santo Amaro project-Recife,2005.] [in Portuguese] *Rev Bras Otorrinolaringol*. 2006 May-June;72(3): 394-9. [CrossRef]
15. Miller AJ, Vargervik K, Chierici

- G. Sequential neuromuscular changes in rhesus monkeys during the initial adaptation to oral respiration. *Am J Orthod.* 1982 Feb;81(2):99-107. [PubMed]
16. Bishara SE, (editor). Textbook of Orthodontics. Philadelphia, W B Saunders Co. 2001. p. 606.
17. Gill DS, Naini FB. Orthodontics: Principles and Practice. Wiley-Blackwell. 2011. p. 281.
18. Rao J, QRS for BDS 4th Year. Pedodontics. Elsevier India. 2014. p. 164.
19. Souki BQ, Pimenta GB, Souki M, Franco LP, Becker HM, Pinto JA. Prevalence of malocclusion among mouth breathing children: do expectations meet reality? *Int J Pediatr Otorhinolaryngol.* 2009 May; 73(5):767-73. [PubMed]
20. Mocellin M, Fugmann EA, Gavazzoni FB, [A cephalometric and otorhinolaryngological study correlated with the degree of nasal obstruction and the pattern of facial growth in orthodontically untreated patients.] [in Portuguese] *Rev Bras Otorrinolaringol.* 2000; 66:116-120.
21. Linder-Aronson S. Effects of adenoidectomy on dentition and nasopharynx. *Am J Orthod.* 1974 Jan; 65(1):1-15.
22. Linder-Aronson S, Woodside DG, Lindstrom A. Mandibular growth direction following adenoidectomy. *Am J Orthod.* 1986 Apr;89(4):273-84. [PubMed]
23. Costa JG, Costa GS, Costa C, Vilella OV, Mattos CT, Cury-Saramago AA. Clinical recognition of mouth breathers by orthodontists: A preliminary study. *Am J Orthod Dentofacial Orthop.* 2017 Nov;152(5):646-653. [PubMed] [CrossRef]
24. Chambi-Rocha A, Cabrera-Domínguez ME, Domínguez-Reyes A. Breathing mode influence on craniofacial development and head posture. *J Pediatr (Rio J).* 2017 Aug 14. pii: S0021-7557(17)30011-6. [Epub ahead of print] [PubMed] [CrossRef]
25. Galievskya M, Lambert A, Sleep respiratory problems in children: Diagnosis and contribution of the orthodontist *Int Orthodontics.* 2017 Sep;15(3): 405-23. [CrossRef]
26. Rossi RC, Rossi NJ, Rossi NJ, Yamashita HK, Pignatari SS. Dentofacial characteristics of oral breathers in different ages: a retrospective case-control study. *Prog Orthod.* 2015;16:23. [PubMed] [CrossRef]
27. El Aouame A, Daoui A, El Quars F. Nasal breathing and the vertical dimension: A cephalometric study. *Int Orthod.* 2016 Dec;14(4):491-502. [PubMed] [CrossRef]
28. Osiatuma VI, Otuyemi OD, Kolawole KA, Ogunbanjo BO, Amusa YB, Occlusal characteristics of children with hypertrophied adenoids in Nigeria. *Int Orthod.* 2015 Mar;13(1):26-42. [PubMed] [CrossRef]
29. Pacheco MC, Fiorott BS, Finck NS, Araújo MT, Craniofacial changes and symptoms of sleep-disordered breathing in healthy children. *Dental Press J Orthod.* 2015 May-Jun;20(3): 80-7. [PubMed] [CrossRef]
30. Malhotra S, Gupta V, Pandey RK, Singh SK, Nagar A, Dental consequences of mouth breathing in the pediatric age group. *Int J Oral Health Sci.* 2013, Jun-Dec;3(2):79-83. [CrossRef]
31. Zalzal GH, Cotton RT. Chapter 68: Pharyngitis and Adenotonsillar Disease. [Internet]
32. Harvold EP, Tomer BS, Vargervik K, Chierici G, Primate experiments on oral respiration. *Am J Orthod.* 1981 Apr; 79(4):359-72. [PubMed]
33. Solow B, Kreiborhg S. Soft tissue stretching: a possible control factor in craniofacial morphogenesis. *J Dent Res.* 1977 Sep; 86(6):505-7.
34. Rubin RM. Mode of respiration and facial growth. *Am J Orthod.* 1980 Nov;78(5):504-10. [PubMed]
35. Harari D, Redlich M, Miri S, Hamud T, Gross M, The effect of mouth breathing versus nasal breathing on dentofacial and craniofacial development in orthodontic patients. *Laryngoscope.* 2010 Oct;120(10):2089-93. [PubMed]
36. Vig KW. Nasal obstruction and facial growth: the strength of evidence for clinical assumptions. *Am J Orthod Dentofacial Orthop.* 1998 June; 113(6): 603-11. [PubMed]
37. Wagaiyu EG, Ashley FP. Mouth breathing, lip seal and upper lip coverage and their relationship with gingival inflammation in 11-14 year-old school-children. *J Clin Periodontol.* 1991 Oct; 18(9):698-702.
38. Joshi MR, Study of dental occlusion in nasal and pro-nasal breathers in Maharashtrian children. *J All India D.A.* 1964; 36:219-39, 247-49
39. McNamara JA, Influence of respiratory pattern on craniofacial growth. *Angle Orthod.* 1981 Oct; 51(4):269-300
40. Huber RE, Reynolds JW. A dentofacial study of male students at the University of Michigan in the physical hardening program. *Am J Orthodont Oral Surg.* 1946. Jan;32(1):1-21, 91.
41. Rakosi T, Schilli W. Class III anomalies: a coordinated approach to skeletal, dental, and soft tissue problems. *J Oral Surg.* 1981 Nov;39(11): 860-70.
42. Pacheco MC, Casagrande CF, Teixeira LP, Finck NS, de Araújo MT, Guidelines proposal for clinical recognition of mouth breathing children. *Dental Press J Orthod.* 2015 Jul-Aug; 20(4):39-44. [PubMed] [CrossRef]
43. Friedman M, Tanyeri H, La Rosa M, Landsberg R, Vaidyanathan K, Pieri S, et al. Clinical predictors of obstructive sleep apnea. *Laryngoscope.* 1999 Dec;109(12):1901-7. [PubMed] [CrossRef]

Please cite this article as: Valcheva Z, Arnautska H, Dimova M, Ivanova G, Atanasova I. The role of mouth breathing on dentition development and formation. *J of IMAB.* 2018 Jan-Mar;24(1):1878-1882. DOI: <https://doi.org/10.5272/jimab.2018241.1878>

Received: 27/06/2017; Published online: 17/01/2018



Address for correspondence:

Zornitsa Valcheva, Department of Orthodontics, Faculty of Dental Medicine, Medical University – Varna.
84, Tsar Osvoboditel Blvd., 9000 Varna, Bulgaria; Tel: +359 883 320 971
e-mail: zornica.valcheva@gmail.com