

# How Does Open-Mouth Breathing Influence Upper Airway Anatomy?

Seung Hoon Lee, MD; Ji Ho Choi, MD; Chol Shin, MD; Heung Man Lee, MD; Soon Young Kwon, MD; Sang Hag Lee, MD

**Objectives/Hypothesis:** Open-mouth breathing during sleep may increase the severity of obstructive sleep apnea (OSA) and complicate nasal continuous positive airway pressure (CPAP) therapy in patients with OSA. The aim of this study was to assess the effect of open-mouth breathing on upper airway anatomy using lateral cephalometry and fiberoptic nasopharyngoscopy.

**Study Design:** This was a cross-sectional study.

**Methods:** Lateral cephalometry and fiberoptic nasopharyngoscopy were carried out on 28 subjects with a mean age of 36.7 years. We compared the effect of the mouth being open or closed on the results in lateral cephalometry (pharyngeal length, distance between the mandible and hyoid bone [MP-H], angles from the sella-nasion to mandibular points A and B [SNA, SNB, respectively], retropalatal, retroglottal, and hypopharyngeal distance) and fiberoptic nasopharyngoscopy (retropalatal and retroglottal cross-sectional area).

**Results:** On lateral cephalometric measurements, retropalatal distance ( $P = .000$ ), retroglottal distance ( $P = .000$ ), and MP-H ( $P = .002$ ) were lower with mouth open, and pharyngeal length ( $P = .000$ ) was greater. However, there were no significant differences in SNA and hypopharyngeal distance. On fiberoptic nasopharyngoscopy, retropalatal ( $P = .005$ ) and retroglottal ( $P = .000$ ) cross-sectional areas were significantly reduced with the mouth open.

**Conclusions:** Open-mouth breathing is associated with reduction of the retropalatal and retroglottal areas, lengthening of the pharynx and shortening of the MP-H in the upper airway. We suggest that knowledge of these

anatomic changes improves our understanding of the increase of OSA severity and the low adherence to nasal CPAP therapy in mouth breathers.

**Key Words:** Mouth breathing, cephalometry, endoscopy, pharynx.

*Laryngoscope*, 117:1102–1106, 2007

## INTRODUCTION

Most healthy subjects choose to breathe almost exclusively by the nasal route rather than the oral route during sleep.<sup>1</sup> However, if there are any obstructions in the nasal or nasopharyngeal pathways, the nasal breathing pattern may change to a mouth breathing pattern to compensate for decreased nasal flow and to allow adequate respiration.<sup>2</sup>

Open-mouth breathing is related to the growth and development of the orofacial structures, including narrowing of the maxilla, reduced development of the mandible, malocclusion, and mouth dryness.<sup>3</sup> It may also affect upper airway collapsibility and resistance.<sup>4–6</sup> In patients with obstructive sleep apnea (OSA), mouth breathing during sleep is a risk factor for increased severity of OSA and for low adherence to nasal continuous positive airway pressure (CPAP) therapy.<sup>7</sup> Furthermore, relief from severe nasal obstruction during sleep is associated with significant normalization of mouth breathing, improvement in sleep-stage architecture, and a modest reduction in OSA severity.<sup>8</sup>

Cephalometry is a readily available, inexpensive, and reliable technique for evaluating the pharyngeal airway.<sup>9,10</sup> However, it provides only a two-dimensional static representation of the upper airway, which is in fact a dynamic three-dimensional structure. Moreover, it only yields information on the linear dimensions of the structures. Fiberoptic nasopharyngoscopy is easily performed in the outpatient setting without exposure to radiation. This procedure permits direct observation of the dynamic appearance of the pharynx in a supine position as well as measurement of cross-sectional areas using an available software program.<sup>11</sup>

We hypothesized that open-mouth breathing during sleep changes upper airway anatomy and that this increases the severity of OSA as well as CPAP noncompliance.

From the Department of Otorhinolaryngology–Head and Neck Surgery (S.H.L., J.H.C., H.M.L., S.Y.K., S.H.L.), College of Medicine, Korea University, Seoul, South Korea; and Respiratory Internal Medicine (C.S.), College of Medicine, Korea University, Seoul, South Korea.

Editor's Note: This Manuscript was accepted for publication February 1, 2007.

This paper was presented at the meeting of the 12th Korean Combined Otolaryngologic Congress, April 21, 2006, Kyungju City, South Korea.

This study was supported by a Korea University Grant.

Send correspondence to Dr. Seung Hoon Lee, Department of Otorhinolaryngology–Head and Neck Surgery, College of Medicine, Korea University, Ansan Hospital, 516 Gojan-Dong, Ansan-City, Gyeonggi-do, 425-020, South Korea. E-mail: shleeent@kumc.or.kr

DOI: 10.1097/MLG.0b013e318042aef7

Therefore, using cephalometry and fiberoptic nasopharyngoscopy to assess the influence of open-mouth breathing on the upper airway, we have examined the changes in the upper airway in response to opening of the mouth.

## MATERIALS AND METHODS

### Subjects

We studied subjects who had no subjective complaints of upper airway obstruction, such as nasal obstruction, snoring, and sleep apnea for at least three months, and in whom physical examination revealed no anatomic problems in the oropharynx or nasal cavity. We excluded subjects with significant maxillofacial deformities, tonsillar hypertrophy (tonsils occupying more than 50% of the lateral dimension of the oropharynx), macroglossia, severe obesity, unwillingness to cooperate, and subjects who had previous upper airway surgery. Height and weight were recorded, and the body mass index (BMI) was calculated. In total, 28 subjects were included in the study. Ages ranged from 17 to 71 years, with a mean of  $36.7 \pm 14.6$  years. There were 16 male participants and 12 female participants. Mean BMI was  $23.3 \pm 2.8 \text{ kg/m}^2$ . The Institutional Review Board of Ansan Hospital, Korea University reviewed and approved the study protocol. Each subject provided written informed consent.

### Lateral Cephalometry

Lateral cephalometric radiographs were taken with the mouth open and closed with the patient in an upright sitting position and awake. Each subject was directed to gaze forward, holding his or her head in a natural position. The first closed-mouth film was taken with the subject occluding the mouth, and the second open-mouth film was taken with the subject breathing through the mouth, which was adequately open in a natural and comfortable state. Seven cephalometric variables, expressed as angular (degrees) or linear (mm) measurements, for both open and closed mouth were analyzed for each subject. Cephalometric measurements included retropalatal distance, retroglossal distance, hypoglossal distance, pharyngeal length, distance between the mandible and hyoid bone (MP-H), and angles from the sella-nasion to mandibular points A and B (angles SNA and SNB, respectively) (Fig. 1). A single experienced clinician digitized and, using STARPACS (Infinit, Seoul, South Korea), calculated all landmarks identified from lateral cephalograms.

### Fiberoptic Nasopharyngoscopy

Endoscopic examination of the upper airway was carried out using a fiberoptic nasopharyngoscope (Olympus ENF Type T3, Tokyo, Japan), with a calibrator (known dimension of 5 mm with the tip open) inserted through the instrument port and placed at

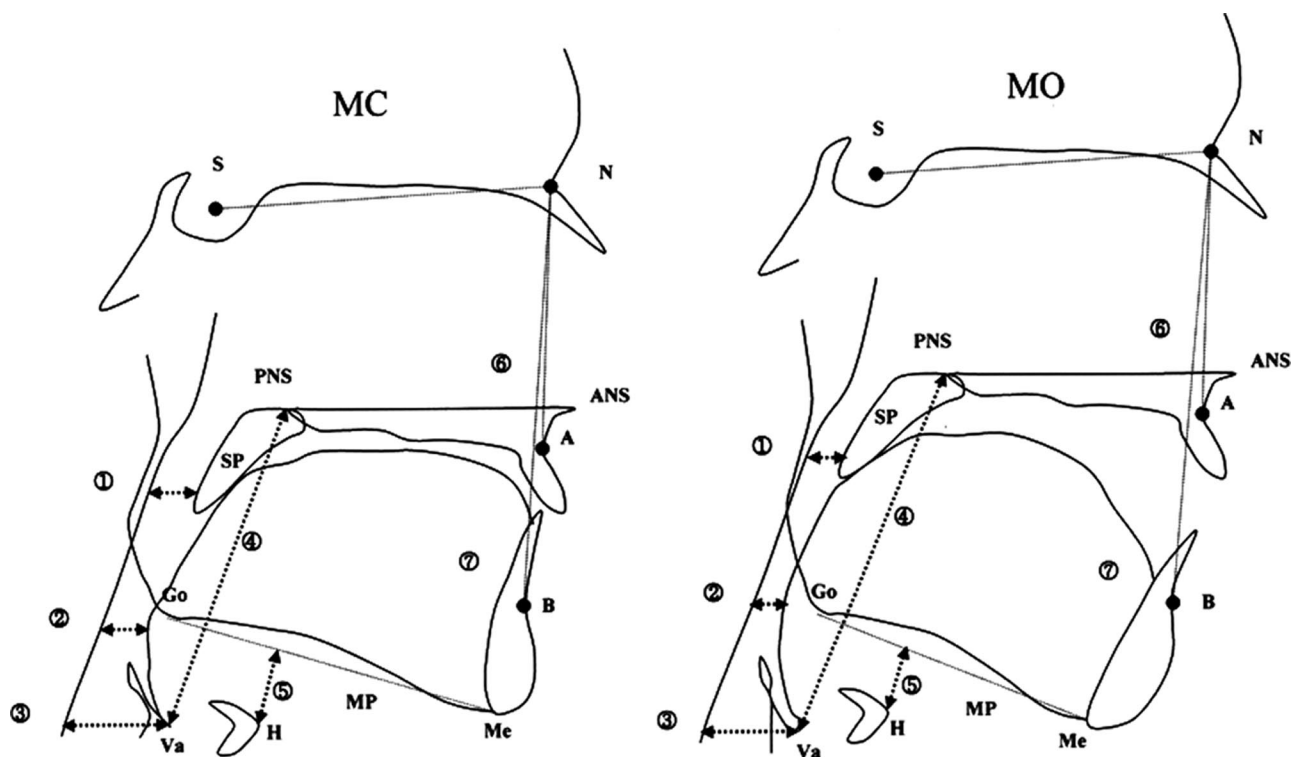


Fig. 1. Standard lateral cephalometric landmarks. MC = mouth closed; MO = mouth open; ① = retropalatal distance (mm): minimal distance from soft palate to posterior pharyngeal wall parallel to maxillary plane; ② = retroglossal distance (mm): minimal distance from tongue base to posterior pharyngeal wall parallel to maxillary plane; ③ = hypopharyngeal distance (mm): minimal distance from vallecula to posterior pharyngeal wall parallel to maxillary plane; ④ = pharyngeal length (mm): distance from posterior nasal spine to vallecula; ⑤ = MP-H (mm): distance from mandibular plane to hyoid bone; ⑥ = SNA ( $^{\circ}$ ): angle formed by intersection of lines drawn from sella to nasion and nasion to subspinale; ⑦ = SNB ( $^{\circ}$ ): angle formed by intersection of lines drawn from sella to nasion and nasion to supramentale. A = subspinale: deepest midline concavity of upper alveolar process; ANS = anterior nasal spine: tip of bony anterior nasal spine; B = supraspinale: deepest midline concavity of lower alveolar process; H = hyoid bone: most anterior and superior point on the body of the hyoid bone; Go = gonion: most posterior inferior point on convexity of angle of mandible; Me = menton: most inferior point on mandibular symphysis; MP = mandibular plane: tangent to lower border of mandible through menton; MxPl = maxillary plane: plane constructed from anterior nasal spine through posterior nasal spine; N = nasion: most anterior point of frontonasal suture in median plane; PNS = posterior nasal spine: tip of bony posterior nasal spine; S = sella: center of sella turcica; SP = soft palate; Va = vallecula: intersection of epiglottis and base of tongue.

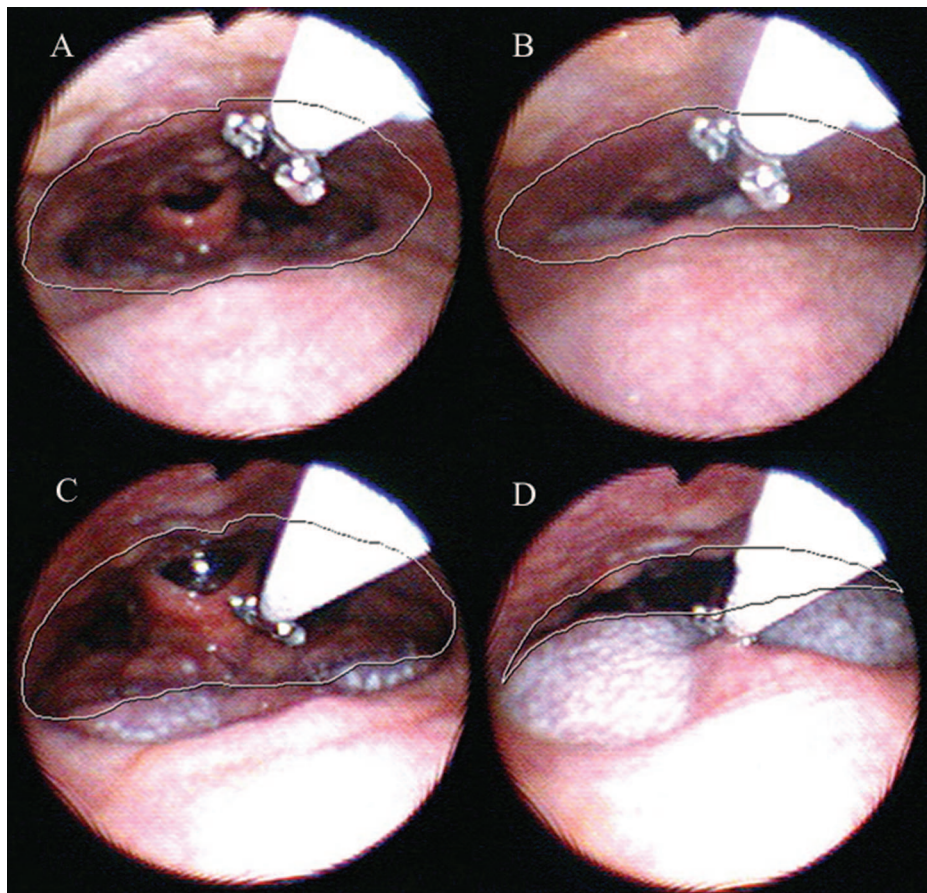


Fig. 2. Fiberoptic nasopharyngoscopic findings. (A) Retropalatal area with mouth closed. (B) Retropalatal area with mouth open. (C) Retroglossal area with mouth closed. (D) Retroglossal area with mouth open. White line indicates the cross-sectional area of the pharynx.

the level of interest. The examination was performed through the nasal cavity with the subject in a supine position and awake. After the entire upper airway had been examined, the tip of the nasopharyngoscope was placed over the narrowest levels of the retropalatal and retroglossal areas. The uvula was used as an anatomic landmark for the retropalatal level and the tip of the epiglottis as a landmark for the retroglossal level. Then, the calibrator was brought to the narrowest area for each level; it was fully opened, and an endoscopic image was taken at the best view. In addition, the surrounding structures, such as the soft palate, tongue base, and posterior and lateral pharyngeal wall, were observed and measured. This examination was performed systematically in the following order: retropalatal area with mouth closed, retropalatal area with mouth open, retroglossal area with mouth closed, and retroglossal area with mouth open. To obtain measurements with mouth breathing, the subject was allowed to breathe through the mouth with adequate and comfortable airflow. The actual cross-sectional areas were obtained using STARPACS (Infinit, Seoul, South Korea) by comparing the dimension of the fully opened calibrator (5 mm) and the measurements of the retropalatal and retroglossal levels in endoscopic images (Fig. 2). A single experienced otolaryngologist performed the endoscopic examination and measurements of the cross-sectional areas for consistency.

### Statistical Analysis

A two-tailed paired *t* test was used to compare cephalometric and fiberoptic nasopharyngoscopic measurements with the mouth open and closed. The standard deviation of the mean (SD) was used as an index of variability. Statistical analysis was performed with the SPSS software programs (SPSS Inc., Chicago, IL), and a *P* < .05 was accepted as statistically significant.

## RESULTS

### Lateral Cephalometry

The cephalometric data are summarized in Table I. Significant changes were found in retropalatal distance, retroglossal distance, pharyngeal length, MP-H (distance between mandibular plane and hyoid bone), and SNB in comparisons between the mouth open and closed. When

TABLE I.  
Comparison of Differences in Cephalometric Results Between Mouth Closed and Mouth Open.

	Mouth Closed	Mouth Open	<i>P</i> Value
Retropalatal distance (mm)	9.39 ± 2.68	6.85 ± 2.96	.000
Retroglossal distance (mm)	11.16 ± 2.57	7.28 ± 2.89	.000
Hypopharyngeal distance (mm)	17.31 ± 3.58	17.57 ± 3.24	.571
Pharyngeal length (mm)	69.66 ± 7.01	77.95 ± 10.52	.000
MP-H (mm)	12.52 ± 4.87	9.56 ± 5.82	.002
SNA (°)	88.48 ± 3.32	88.53 ± 3.62	.887
SNB (°)	85.41 ± 3.17	81.69 ± 4.27	.000

Data are presented as mean ± SD.

MP = mandibular plane; H = hyoid bone; SNA = angle formed by intersection of lines drawn from sella to nasion and nasion to subspinale; SNB = angle formed by intersection of lines drawn from sella to nasion and nasion to supramentale.



TABLE II.  
Comparison of Differences in Cross-Sectional Area of Upper Airway on Fiberoptic Nasopharyngoscopy Between Mouth Closed and Mouth Open.

	Mouth Closed	Mouth Open	P Value
Retropalatal CSA (mm <sup>2</sup> )	70.71 ± 20.34	62.13 ± 20.56	.005
Retroglossal CSA (mm <sup>2</sup> )	137.33 ± 58.28	78.07 ± 35.60	.000

Data are presented as mean ± SD.  
CSA = cross-sectional area.

compared with the mouth closed, the retropalatal and retroglossal distances and MP-H were each significantly lower than with the mouth open, as was the SNB angle. Pharyngeal length was also significantly greater. However, hypoglossal distance and SNA showed no statistically significant differences.

### Fiberoptic Nasopharyngoscopy

The fiberoptic nasopharyngoscopic data are presented in Table II. Retropalatal and retroglossal cross-sectional areas were significantly lower when the mouth was opened than when it was closed.

### DISCUSSION

We have shown that there are significant anatomic changes in the upper airway with opening of the mouth. There is a significant narrowing of the retropalatal distance with the mouth open. This may be caused by the posterior displacement of the soft palate, which is in contact with the posteriorly displaced tongue base when the mouth is open. In addition, the retropalatal distance is reduced by posterior movement of the soft palate against the posterior pharyngeal wall to close the nasopharyngeal airway and breathe by the oral route. The reduction of the retroglossal distance may be caused by posteroinferior movements of the mandible and tongue. However, no change of hypopharyngeal distance takes place because the hypopharyngeal segment is supported by rigid structures such as the thyroid cartilage in contrast to the retropalatal and retroglossal pharyngeal segments that are supported by collapsible soft tissues. The distance between mandibular plane and hyoid bone (MP-H) is significantly reduced with the mouth open. This change, which could shorten the upper airway dilator muscles located between the mandible and hyoid bone, may alter the contraction efficiency and reduce the contractile force of the dilator muscles by producing an unfavorable length-tension relationship.<sup>5</sup> We also have found that open-mouth breathing is associated with an increase in pharyngeal length. The faster airflow generated by the longer and narrower upper airway may increase the negative intraluminal pressure during inspiration and facilitate collapse of the upper airway.

Bachour and Maasilta<sup>7</sup> reported that patients who breathe mainly through their mouth during sleep have a higher respiratory disturbance index than those who breathe mainly through their nose. McLean et al.<sup>8</sup> demonstrated that relief from severe nasal obstruction in patients with normal retroglossal airway is associated with a

reduction in mouth breathing and in OSA severity during sleep. Our findings suggest that relief from nasal obstruction may indirectly contribute to the reduction of OSA severity because of the changes of the upper pharyngeal airway by the normalization of mouth breathing.

CPAP therapy, which provides a mechanical pneumatic stent for the upper airway, is an effective treatment for OSA.<sup>12</sup> It is traditionally given via a nasal mask, and therefore patients should ideally keep their mouth closed during sleep. However, the mouth may fall open during sleep, and this causes leaks in 10% to 15% of cases.<sup>13</sup> To compensate for such air leaks, the pressure generator in the CPAP increases nasal airflow. This may lead to nasal mucosal inflammation, edema, and nasal obstruction, which can promote CPAP intolerance.<sup>14–16</sup> Patients with moderate to severe OSA with a high percentage of mouth breathing during sleep are less adherent to nasal CPAP therapy than patients with a low percentage of mouth breathing.<sup>7</sup> Our findings suggest that mouth breathing may not only lead to loss of air pressure due to leakage around the mouth during nasal CPAP therapy but can also increase the titrating pressure by reducing the retropalatal and retroglossal areas. In addition, the changes of upper airway dilator muscles and pharyngeal length may facilitate collapse of the upper airway and increase its resistance, thus aggravating the need for more airflow or positive pressure. The additional airflow or positive pressure can in turn cause rhinitis, nasal obstruction, or discomfort, which finally affect CPAP compliance.

There are several limitations to this study. Cephalometric and fiberoptic nasopharyngoscopic measurements are two-dimensional static representations of an active three-dimensional upper airway. Furthermore, because both examinations were performed during wakefulness, and cephalometry was performed in an upright sitting position, these examinations do not necessarily reflect the actual sleep state. However, because with subjects in the supine position the soft palate and tongue base are displaced posteriorly due to gravity and because the activity of upper airway dilator muscle decreases during sleep, the cross-sectional areas of the retroglossal and retropalatal areas during sleep may be narrower than when subjects are in an upright sitting position during wakefulness.<sup>17,18</sup>

### CONCLUSION

Open-mouth breathing significantly narrows the retropalatal and retroglossal areas, lengthens the pharynx, and shortens the MP-H. Knowledge of these changes associated with opening of the mouth adds to our understanding of the increase of OSA severity and low adherence to nasal CPAP therapy in mouth breathers.

### BIBLIOGRAPHY

1. Fitzpatrick MF, Driver HS, Chatha N, Voduc N, Girard AM. Partitioning of inhaled ventilation between the nasal and oral routes during sleep in normal subjects. *J Appl Physiol* 2003;94:883–890.
2. Harvold EP, Tomer BS, Vargervik K, Chierici G. Primate experiments on oral respiration. *Am J Orthod* 1981;79:359–372.
3. Bresolin D, Shapiro PA, Shapiro GG, Chapko MK, Dassel S. Mouth breathing in allergic children: its relationship

- to dentofacial development. *Am J Orthod* 1983;83:334–340.
4. Fitzpatrick MF, McLean H, Urton AM, Tan A, O'Donnell D, Driver HS. Effect of nasal or oral breathing route on upper airway resistance during sleep. *Eur Respir J* 2003;22:827–832.
  5. Meurice JC, Marc I, Carrier G, Series F. Effects of mouth opening on upper airway collapsibility in normal sleeping subjects. *Am J Respir Crit Care Med* 1996;153:255–259.
  6. Isono S, Tanaka A, Tagaito Y, Ishikawa T, Nishino T. Influences of head positions and bite opening on collapsibility of the passive pharynx. *J Appl Physiol* 2004;97:339–346.
  7. Bachour A, Maasilta P. Mouth breathing compromises adherence to nasal continuous positive airway pressure therapy. *Chest* 2004;126:1248–1254.
  8. McLean HA, Urton AM, Driver HS, et al. Effect of treating severe nasal obstruction on the severity of obstructive sleep apnoea. *Eur Respir J* 2005;25:521–527.
  9. Hsu PP, Tan AK, Chan YH, Lu PK, Blair RL. Clinical predictors in obstructive sleep apnoea patients with calibrated cephalometric analysis: a new approach. *Clin Otolaryngol* 2005;30:234–241.
  10. Mochizuki T, Okamoto M, Sano H, Naganuma H. Cephalometric analysis in patients with obstructive sleep apnea syndrome. *Acta Otolaryngol Suppl* 1996;524:64–72.
  11. Hsu PP, Tan BY, Chan YH, Tay HN, Lu PK, Blair RL. Clinical predictors in obstructive sleep apnea patients with computer-assisted quantitative videoendoscopic upper airway analysis. *Laryngoscope* 2004;114:791–799.
  12. Gordon P, Sanders MH. Sleep. Part 7. Positive airway pressure therapy for obstructive sleep apnoea/hypopnoea syndrome. *Thorax* 2005;60:68–75.
  13. Rapoport DM. Methods to stabilize the upper airway using positive pressure. *Sleep* 1996;19:S123–S130.
  14. Berry RB. Improving CPAP compliance: man more than machine. *Sleep Med* 2000;1:175–178.
  15. Richards GN, Cistulli PA, Ungar RG, Berthon-Jones M, Sullivan CE. Mouth leak with nasal continuous positive airway pressure increases nasal airway resistance. *Am J Respir Crit Care Med* 1996;154:182–186.
  16. Hayes MJ, McGregor FB, Roberts DN, Schroter RC, Pride NB. Continuous nasal positive airway pressure with a mouth leak: effect on nasal mucosal blood flux and nasal geometry. *Thorax* 1995;50:1179–1182.
  17. Prachartam N, Hans MG, Strohl KP, Redline S. Upright and supine cephalometric evaluation of obstructive sleep apnea syndrome and snoring subjects. *Angle Orthod* 1994;64:63–73.
  18. Pae EK, Lowe AA, Sasaki K, Price C, Tsuchiya M, Fleetham JA. A cephalometric and electromyographic study of upper airway structures in the upright and supine positions. *Am J Orthod Dentofacial Orthop* 1994;106:52–59.